

ROLE OF ATT IN MULTIVARIATE MANIFESTATIONS OF TUBERCULOUS POSTERIOR UVEITIS

A. Nandhini¹, Ganapathi Rajesh², Hemapriya³

¹Associate Professor, Department of Ophthalmology, Madras Medical College, India.

²Professor, Department of Ophthalmology, Theni Medical College, India.

³Assistant Professor, Department of Ophthalmology, Madras Medical College, India.

Received : 08/01/2023
Received in revised form : 14/02/2023
Accepted : 23/02/2023

Keywords:

Posterior segment uveitis, anti-tuberculous treatment, ocular tuberculosis.

Corresponding Author:

Dr. Nandhini Arumugam,

Email: dr.nandhiniarumugam@gmail.com

DOI: 10.47009/jamp.2023.5.4.146

Source of Support: Nil,
Conflict of Interest: None declared

Int J Acad Med Pharm
2023; 5 (4); 731-737



Abstract

Background: Posterior segment uveitis is a potentially blinding condition. We aim to report varied clinical presentations of ocular tuberculosis and importance of its therapeutic response to anti-tuberculous treatment in a cohort of patients treated in tertiary care hospital, for presumed “ocular tuberculosis”, based on clinical findings, systemic assessment and specific testing for tuberculosis. **Materials and Methods:** We found that in our study, of 4 cases, 3 had vision improvement after starting anti-tuberculous treatment and steroids, 1 case treatment is started and the patient is under follow up. **Results:** Patients having a uveitis phenotype consistent with tuberculosis, and other uveitic causes being excluded, then, anti-tuberculous treatment is likely to have a beneficial effect by reducing the risk of visual sequelae. **Conclusion:** Posterior segment uveitis, anti-tuberculous treatment, ocular tuberculosis.

INTRODUCTION

Tuberculosis (TB) is caused by infection with the intracellular acid fast bacillus, *Mycobacterium tuberculosis*. Complex interaction between the host immune response and the bacillus, determines the outcome. Intraocular inflammation, is generally termed as “uveitis”, may result from idiopathic, infectious and non-infectious causes such as post trauma, post-surgery.

Ocular Tuberculosis represent a major diagnostic and therapeutic challenge, due to its heterogenous clinical manifestation, mixed ocular tissue involvement, lack of diagnostic criteria and gold standard test and lack of international agreement on the therapeutic approach. Reported Prevalence of Tuberculous uveitis is 0.2 to 2.7% in nonendemic regions and 5.6% to 10.5% in highly endemic areas such as India. Intraocular TB has wide clinical spectrum such as Anterior uveitis (granulomatous /chronic uveitis), Intermediate uveitis, Posterior uveitis (retinal vasculitis, serpiginous like choroiditis, choroidal tubercles or granuloma, subretinal abscess) or Panuveitis.

Aim and objective

The aim of our study is to describe the varied clinical presentations of ocular tuberculosis and importance of its therapeutic response to anti-tuberculous treatment.

MATERIALS AND METHODS

The patients presented to the uvea and medical retina services, underwent a full ophthalmic examination and were assessed with regard to the site and severity of their uveitis, using the SUN criteria.

Ocular investigations like fundus photography, fundus fluorescein angiography are done. Routine laboratory blood tests are done. Systemic investigations such as Mantoux, chest X-ray, HRCT chest, interferon-gamma assay are done.

Fundus photography was done to document the clinical signs in posterior, intermediate and pan uveitis. Fundus fluorescein angiography was done to delineate the active and inactive lesions, and to differentiate tuberculous retinal vasculitis from other forms of vasculitis.

The diagnosis of presumed ocular TB is made based on ophthalmic findings and laboratory results. We referred these patients to thoracic physician for further physical assessment. Any concurrent pulmonary or other extra-pulmonary TB manifestations were evaluated. Patients were then started on Anti-TB therapy and Corticosteroid therapy was administered after commencement of anti TB therapy and the patients are followed up.

Case Reports

Case 1

A 19 year old male came with complaints of sudden loss of vision in left eye for 2 weeks. On ocular examination, his visual acuity in Left eye was 1/60

NIG NIP ,with RAPD ,with otherwise normal anterior segment .Visual acuity, Color Vision and fields in Right eye were within normal limits. Fundus examination of left eye revealed Vitritis, hyperemic disc with blurring of margins, hemorrhages and exudates along vessels and around macula. Fundus fluorescein angiography of left eye showed capillary non perfusion areas and neovascularization. He underwent routine laboratory blood tests, Mantoux test, HRCT chest -all investigations found to be normal. He was then started on Anti-TB therapy, followed by Inj Intravenous Methyl prednisolone under pulmonologist guidance. Panretinal photocoagulation was further planned to left eye to prevent further neovascular proliferation. Following treatment, his vision significantly improved to 6/18 ,with resolution of exudates in left eye and he is under follow up.

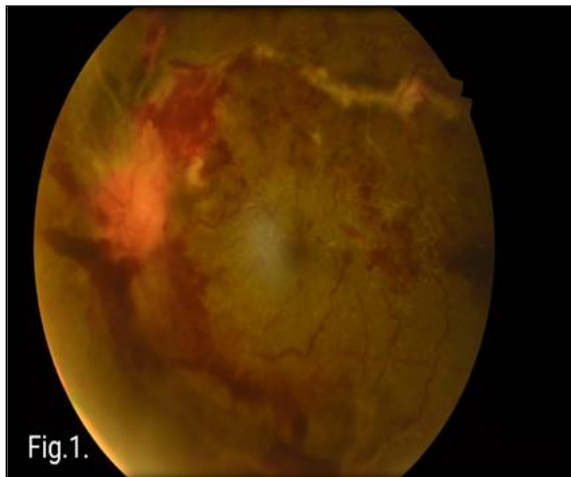


Figure 1: Fundus photography of Left eye of case 1, image showing hyperemic disc with extensive exudates and hemorrhages at the time of presentation

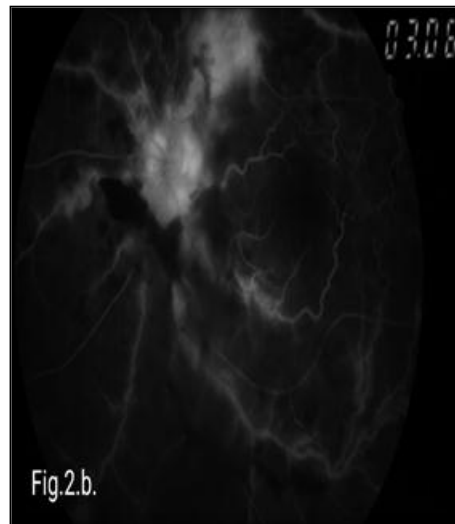
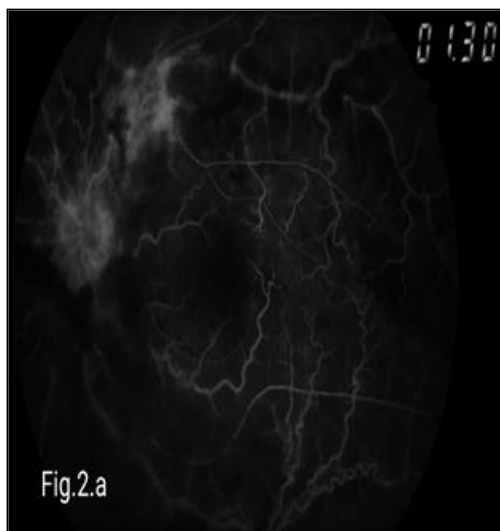


Figure 2a and 2b: Fundus fluorescein angiography of Left eye of case 1, image showing capillary non perfusion areas and neovascularization with leakage in late phase

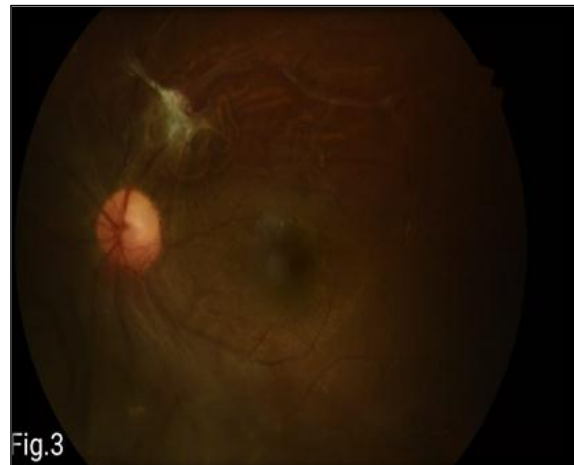

Figure 3: Fundus photography of Left eye of case 1 , image showing well defined disc margins with few exudates and resolved hemorrhages , after treatment with ATT and corticosteroids

Case 2

A 21 year old male came with complaints of sudden loss of vision in left eye for 10 days. On ocular examination, his visual acuity in Left eye was CFCF ,with RAPD ,with otherwise normal anterior segment .Visual acuity, Color Vision and fields in Right eye were within normal limits. Fundus examination of left eye revealed mild nasal margin blurring, plenty of exudates in posterior pole, superficial hemorrhages, sheathing of vessels and venous engorgement. Fundus fluorescein angiography of left eye showed Capillary non perfusion areas in inferior quadrant with enlargement of Foveal avascular zone and neovascularization. He underwent routine laboratory blood tests, Mantoux test, HRCT chest -all investigations found to be normal. He was then started on Anti-TB therapy, followed by Inj Intravenous Methyl prednisolone under pulmonologist guidance. Panretinal

photocoagulation was further planned to left eye to prevent further neovascular proliferation. Following treatment, his vision significantly improved to 6/18 with resolution of exudates in left eye ,and he is under follow up.

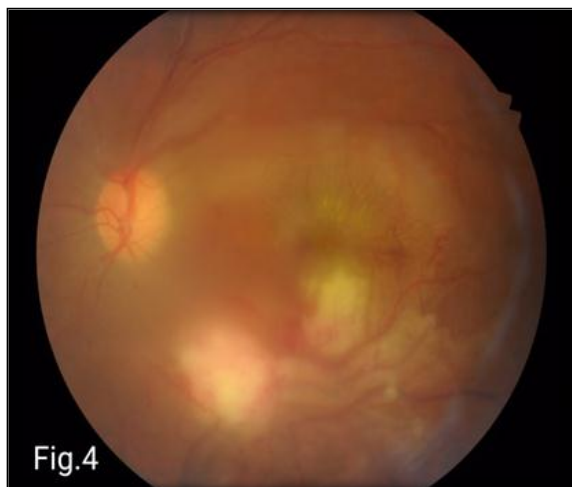


Figure 4: Fundus photography of Left eye of case 2, image showing mild nasal margin blurring of disc with extensive exudates and hemorrhages, sheathing of vessels at the time of presentation

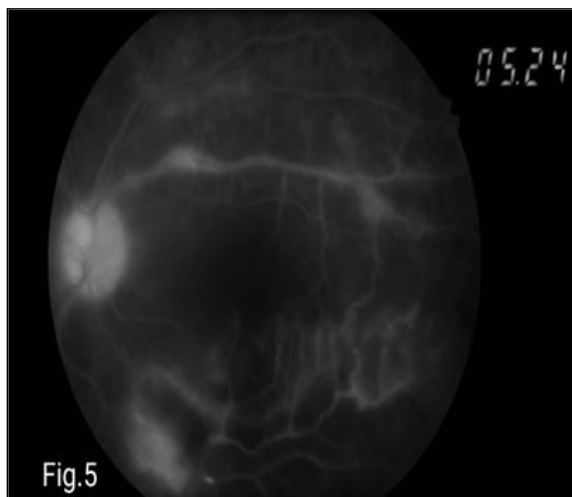


Figure 5: Fundus fluorescein angiography of Left eye of case 2, image showing capillary non perfusion areas and neovascularization with leakage in late phase

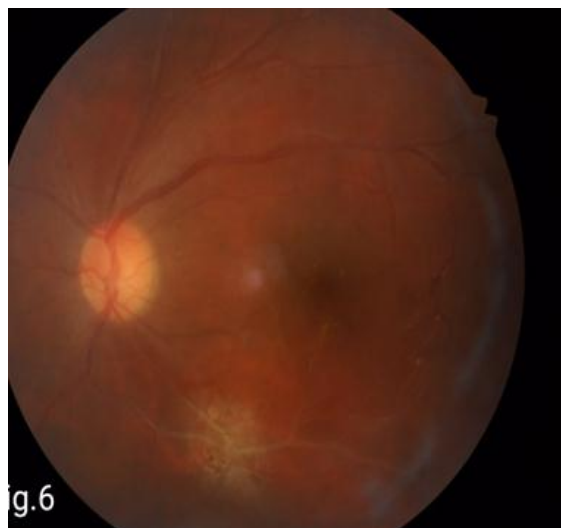

Figure 6: Fundus photography of Left eye of case 2, image showing well defined disc margins with few exudates and resolved hemorrhages, after treatment with ATT and corticosteroids

Case 3

A 49 year old female came with complaints of defective vision in left eye for 1 year. She is a type 2 diabetic and hypertensive on treatment for 10 years. On ocular examination, her visual acuity in both eyes were 6/9 improving to 6/6. Anterior segment was normal in both eyes. Fundus examination of both eyes revealed Multiple sub retinal greyish white lesions scattered in the posterior pole and mid periphery, with pigmentary changes seen in centre of lesion and adjacent Serpiginous like choroiditis. Fundus fluorescein angiography of both eyes showed normal filling pattern with multiple hyperfluorescent spots seen in early choroidal phase, which corresponds to the greyish white lesions in fundus, which decrease in the late phase, suggestive of window defects. Few hypofluorescent spots seen corresponding to the pigmentary lesions in fundus suggestive of blocked fluorescence. Suggestive of HEALED LESIONS. She underwent routine laboratory blood tests, Mantoux test, HRCT chest with mantoux test being positive (12 mm) and other investigations being normal. She was diagnosed as Clinically Suspected Extrapulmonary Tuberculosis (Choroiditis), and then started on Anti-TB therapy and followed by Inj Intravenous Methyl prednisolone, under pulmonologist guidance. Following treatment, her vision was 6/6 in both eyes and she is under follow up.

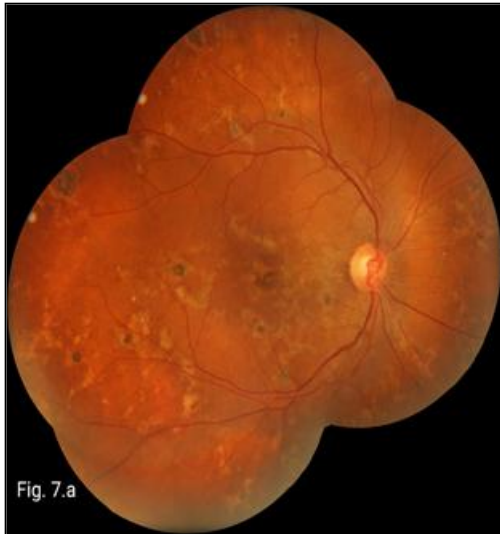

Fig. 7.a

Figure 7.a.: Fundus photography of RE

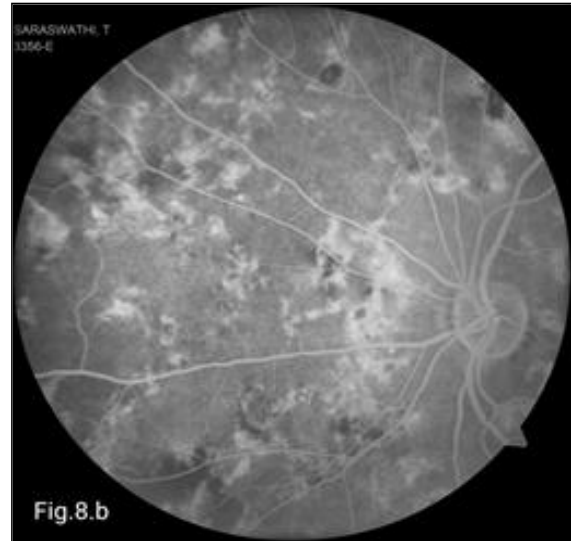


Fig. 8.b

Figure 8.b

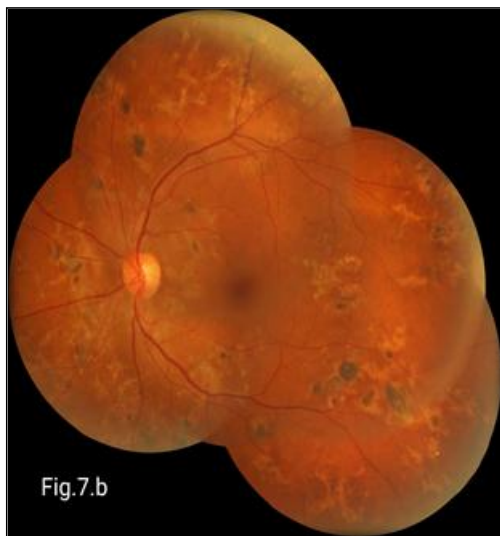

Fig.7.b

Figure 7.b: Fundus photography of LE

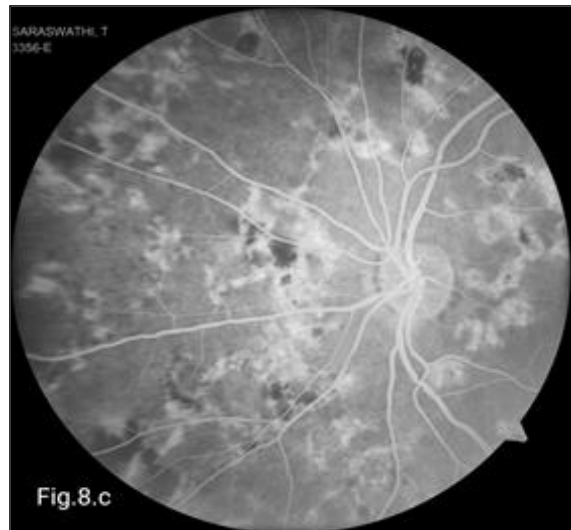


Fig.8.c

Figure 8.C

Figure 7.a and 7.b: Fundus photography of case 3, images showing Vertiginous like choroiditis lesions

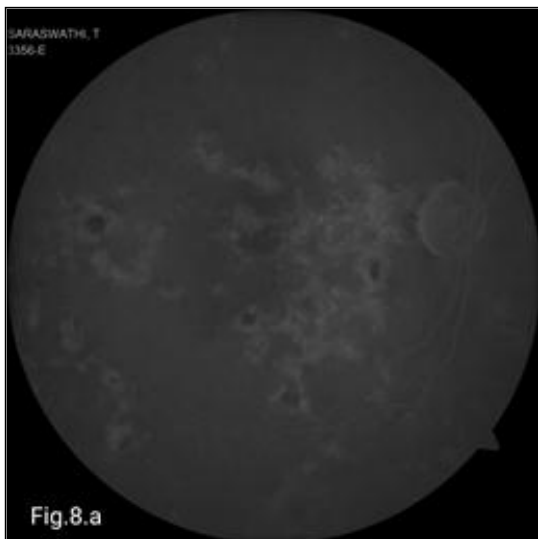


Fig.8.a

Figure 8.a

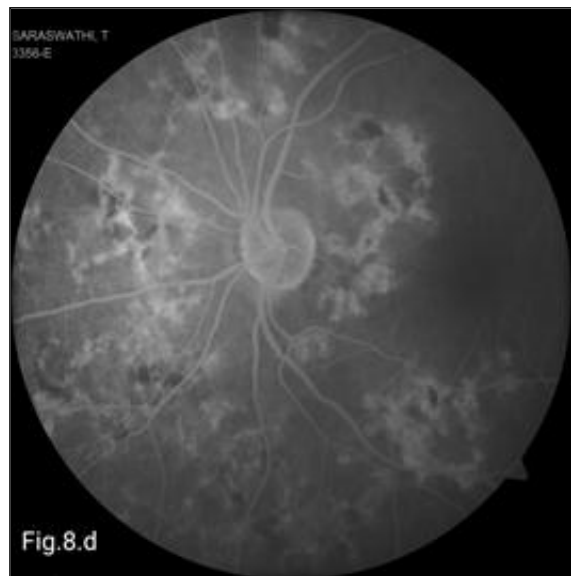


Fig.8.d

Figure 8.D

FIGURE 8.a to 8.d -Fundus fluorescein angiography of Right eye of case 3, images showing multiple

hyperfluorescent spots seen in early choroidal phase, which decrease in the late phase suggestive of window defects, with few hypofluorescent spots seen corresponding to the pigmentary lesions in fundus, suggestive of blocked fluorescence, S/O HEALED LESIONS

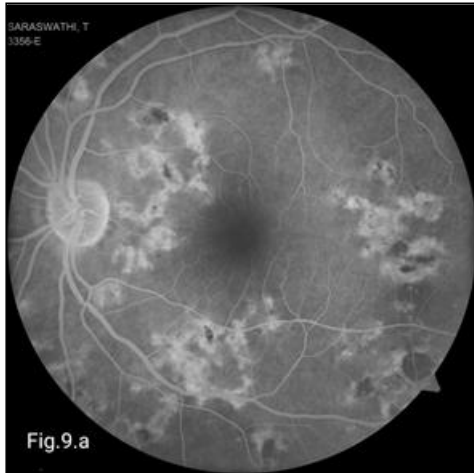


Figure 8.E

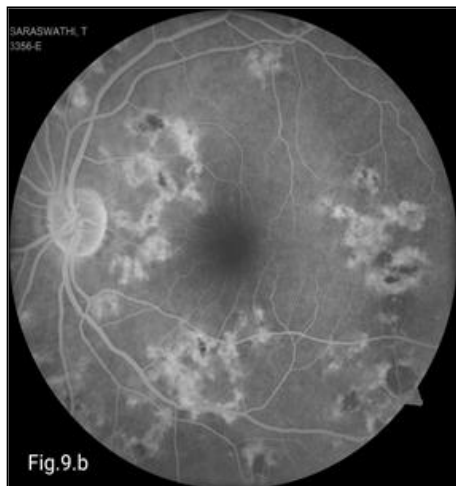


Figure 8.F

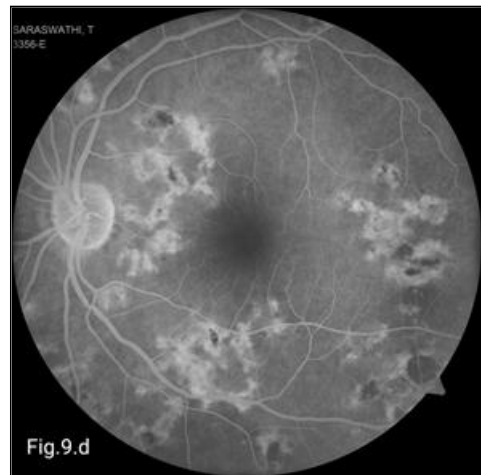
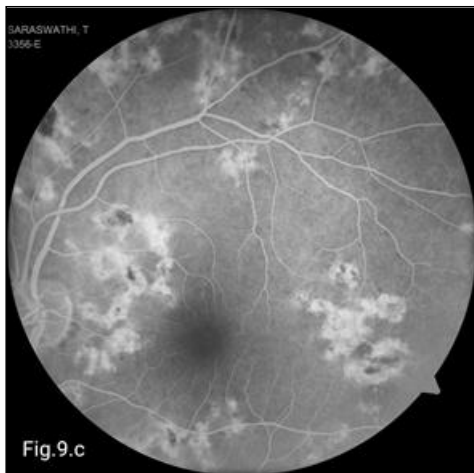


FIGURE 9.a to 9.d -Fundus fluorescein angiography of Left eye of case 3, images showing multiple hyperfluorescent spots seen in early choroidal phase, which decrease in the late phase suggestive of window defects, with few hypofluorescent spots seen corresponding to the pigmentary lesions in fundus, suggestive of blocked fluorescence, S/O HEALED LESIONS

Case 4

A 26 year old male came with complaints of defective vision and floaters in both eyes for 1 year. He was diagnosed with ocular TB, completed 6 months of ATT and lost follow up. On ocular examination, his visual acuity in Right eye was 2/60 NIG NIP, and of left eye 6/12 improving to 6/9, with otherwise normal anterior segment in both eyes . Fundus examination of Right eye revealed few vitreous cells, vitritis with multiple choroiditis patches, exudation along the vessel nasal to the disc, active chorioretinitis patch temporal to macula. Fundus examination of Left eye revealed vitritis, mild venous dilatation, chorioretinitis patch in inferior quadrant. He underwent routine laboratory blood tests, Mantoux test, HRCT chest . Mantoux test was found to be positive(30 mm).HRCT showed enlarged lower paratracheal and perivascular nodes, linear atelectasis in superior segment of right upper lobe ?infective pathology. He was advised to start Anti-TB therapy, followed by corticosteroids by pulmonologist. He is started with ATT and corticosteroids and is under follow up.

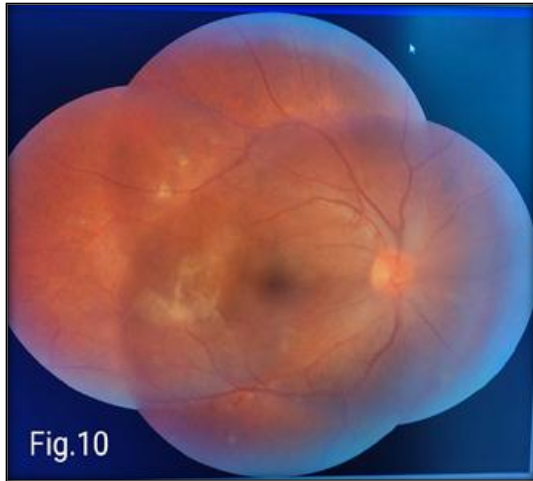

Figure 10: Fundus photography of right eye of case 4, images showing multiple choroiditis patches with exudation, with active chorioretinitis patch temporal to macula

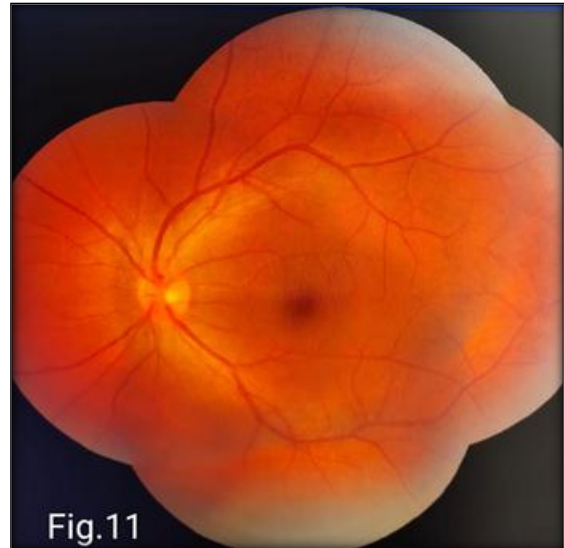

Figure 11: Fundus photography of left eye of case 4, image showing mild venous dilatation with chorioretinitis patch in inferior quadrant

Chart 1: Summary of our case series study

| CASE | AGE/ GENDER | EYE INVOLVED | VISION | OCULAR FINDINGS | INVESTIGATION | TREATMENT | POST TREATMENT VISION |
|--------|---------------------------|-----------------|----------------------------|--|--|-----------------------------|-----------------------------|
| | | | | | | | |
| Case 1 | 19 year/male | Left | Jan-60 | RAPD + | FFA-CNP areas | ATT,steroids | 18-Jun |
| | | | NIG NIP | FUNDUS- vitritis,hyperemic disc, | PPD(Mantoux)- negative | | |
| | | | | Occlusive vasculitis | Xray chest- normal | | |
| | | | | ANTERIOR SEGMENT- Normal | | | |
| Case 2 | 21 year/male | Left | CFCF | RAPD + | FFA-CNP areas | ATT,steroids | 18-Jun |
| | | | | FUNDUS- vitritis, nasal disc margin blurring,Exudate in the posterior pole with vasculitis | PPD(Mantoux)- negative Xray chest- normal | | |
| | | | | ANTERIOR SEGMENT- Normal | | | |
| | | | | | | | |
| Case 3 | 49 year/female | Both | 6/9 improving to 6/6 | FUNDUS- serpiginous like choroiditis lesions | FFA-Healed choroiditis | ATT,steroids | 6-Jun |
| | K/c/o T2DM and SHTN | | | ANTERIOR SEGMENT- Normal | PPD(Mantoux)- 12mm | | |
| | | | | | Positive | | |
| | | | | | Xray chest- normal | | |
| Case 4 | 26 year/male | Both | RE)2/60 NIG NIP | FUNDUS- | PPD(Mantoux)- | ATT followed by steroids | - |
| | | | LE)6/9 | Both eyes- disseminated choroiditis with vitritis ,in addition to vitreous cells ++ in Right eye | 30mm Positive | is started | |
| | | | | | CT CHEST- enlarged lower paratracheal and perivascular node,atelectasis- right upper lobe | and under follow up | |
| | | | | ANTERIOR | | | |

| | | | | | | | |
|--|--|--|--|--------------------|--|--|--|
| | | | | SEGMENT- Normal | | | |
| | | | | | | | |

tuberculous treatment, PPD - Purified protein derivative

DISCUSSION

Ocular tuberculosis on account of its paucibacillary nature, remains a diagnostic conundrum. Ocular TB can cause moderate to severe visual impairment in up to 40% of affected eyes.

This study highlights that the patient cohort is diverse, and strict diagnostic criteria are absent, requiring a high degree of clinical judgment and collaboration between specialists when treating such patients, resulted in beneficial visual outcome in the patients. In our study, corticosteroids were initiated under the cover of Anti-tuberculous therapy. Post-treatment, the ocular inflammation was grossly reduced and the vision improved and also the fundus lesions were reduced in size.

Erika Marie Damato et al study.^[6] showed that some patients experiencing significant delays in starting on ATT, showed that even such patient displayed a clear benefit from treatment.

In endemic country like India, even atypical presentations of ocular TB should be picked up with a high index of suspicion. Follow-up should be of prime importance in both active and resolving phases of the disease, to prevent adverse visual outcome and also for close monitoring of the recurrence of lesions.

According to Collaborative tuberculosis study (COTS), even PCR –positivity or negativity does not influence the treatment of the disease in real world scenario, due to low sensitivity and lack of standardisation.^[3]

Unfortunately, there are no published trials determining ideal treatment regimens. Most papers published are retrospective case series (without control groups), often small in size, treatment was not standardised resulting in high risk of bias.

CONCLUSION

Ocular tuberculosis may be present despite a lack of clinical or radiological evidence of pulmonary TB, particularly in immunosuppressed individuals. Hence, the patient approach should be holistic and integrated with a high degree of suspicion in an endemic country, like India. Collaborating with other specialists like pulmonologist, radiologist, pathologist, microbiologists helps us to tackle the diagnostic conundrum and timely institution of treatment, resulting in beneficial visual outcomes in patients.

Financial support and sponsorship.

Nil.

Conflicts of interest there are no conflicts of interest

REFERENCES

1. Bansal R, Gupta A, Guota V, Dogra MR, Bambery P, Arora SK. Role of antitubercular therapy in uveitis with latent/manifest tuberculosis. *AM J Ophthalmol* 2008;146:772-779.
2. Alvarez s, mccabe wr. extra pulmonary tuberculosis revisited: a review of experience at Boston City and other hospitals. *Medicine(Baltimore)* 1984;63:25-55.
3. Agrawal R, Testi I, Mahajan S, Yuen YS, Agarwal A, Kon OM, Barisani-Asenbauer T, Kempen JH, Gupta A, Jabs DA, Smith JR, Nguyen QD, Pavesio C, Gupta V; Collaborative Ocular Tuberculosis Study Consensus Group. Collaborative Ocular Tuberculosis Study Consensus Guidelines on the Management of Tubercular Uveitis-Report 1: Guidelines for Initiating Antitubercular Therapy in Tubercular Choroiditis. *Ophthalmology*. 2021 Feb;128(2):266-276. doi: 10.1016/j.ophtha.2020.01.008. Epub 2020 Jan 11. PMID: 32115264
4. Rao NA, Saraswathy S, Smith RE. Tuberculous uveitis: distribution of mycobacterium tuberculosis in the retinal pigment epithelium. *Arch Ophthalmol*. 2006;124:1777-1779
5. Sanghvi C, Bell C, Woodhead M, Hardy C, Jones N. Presumed tuberculous uveitis: diagnosis, management, and outcome. *Eye (Lond)*. 2011;25: 475-480
6. Damato et al. *Journal of Ophthalmic Inflammation and Infection* (2017) 7:23 DOI10.1186/s12348-017-0141-4.